



Effect of Sublethal Concentrations of Cadmium on the Histo-pathological Changes of Muscles of *Planiliza abu* Juveniles (Heckel, 1843)

Entesar SH. Hashim & Rajaa N. Al-Yassein

Department of Fisheries and Marine Resources, College of Agriculture, University of Basrah, Iraq

*Corresponding author: r_alyassein@yahoo.com

Received 16 July 2020; Accepted 25 October 2020; Available online 13 November 2020

Abstract: Water heavy metals contamination is an international issue due to its detrimental impact on the environment, aquatic organisms and impairment of the ecological balance systems. Cadmium is a heavy metal that is extremely toxic, even in low doses, thus it is a big concern to the ecosystem. Cd can cause several Patho-morphological changes in various organs in fish. This study was evaluated the effect of sublethal concentrations of Cd toxicity and effects on Histopathological of muscle tissues of *Planiliza abu* Juvenile. Series of Cd concentrations (0.5- 2) ppm were used and the 15d LC₅₀ was 0.4 ppm. Several histopathological alterations were observed which increase gradually with increased concentration, included, marked thickening and hypertrophy of muscle bundle were will observed in lowest concentration (0.5 ppm). While in the highest concentration (2 ppm), atrophy, splitting, and separation with intracellular edema were marked in fish muscle bundle.

Key words: *Planiliza abu*. Cadmium. Sublethal concentrations. Muscles. Histopathology.

Introduction

Human activities play a big role to increase metal pollution in waters (Popek *et al.*, 2006). Because it is threatening aquatic life, available in ecosystem (Abo El Ella *et al.*, 2005) and their persistence in the environment (Biswas *et al.*, 2012). Heavy metals might be entered from different sources such as soil and anthropogenic activities (Abo El Ella *et al.*, 2005) such as, use of fertilizers and pesticides in agriculture and decomposition of organic matter (Bai *et al.*, 2010). Some metals are considered potentially toxic (As, Cd, Pb, Hg, etc.), while others are essential (Cu, Zn, Fe and Mn) (Biswas *et al.*, 2012). Cadmium is an extremely toxic metal, even in low doses. It is used in industry specifically in

electroplating, industrial paints and batteries (Taylor, 1997). Cd is a natural element nonessential element, due to its ability to transfer, deposition and dissolved within ecosystems, this leads to concerns in terms of accumulation in the aquatic food chain (Guardiola *et al.*, 2013). Cd element and its concentrations have been detected in the air, water, soil, and plants (Amdur *et al.*, 1992). Cd serves as a big concern to the ecosystem, because it has the ability to accumulate in living organism (Mohamed, 2008). Raissy *et al.* (2011) found the presence of Cd in the aquatic animals and ecosystem only in the range of trace concentrations. The concentration of Cd range in the ocean seawater from approximately (0.01-42) $\mu\text{g.l}^{-1}$

(Soares *et al.*, 2008). Over time the pollution affecting fish could cause dangerous human health problems by concentrated in an aquatic marine. (Authman *et al.*, 2012). Environmental pollutants can induce oxidative stress in aquatic animals (Ceyhun *et al.*, 2011), for example, Cd can cause hyperactivity and excitability in animals, which can lead to muscular fatigue. Muscle tissue can have direct contact with pollutants (Das & Mukherjee, 2000). Cd also can cause several patho-morphological changes which can be showed in different tissues of aquatic fish. (Beširović *et al.*, 2010).

Humans can be exposed to metals through many routs such as, lungs and skin, drinking contaminated water, and eating contaminated food (Wright & Welbourn, 2002). The impact of Cd toxicity on human health showed on Minamata was Itai-Itai (Ouch-Ouch) Disease in Japanese people (Jintsu River Basin) with many symptoms such as complains of joint, bone, and muscle pains and severe kidney dysfunction (Landis *et al.*, 2003; Bradl, 2005). Cd is toxic to humans when the daily intake is 250 to 300 micrograms (Wright & Welbourn, 2002) and it is found highly persistent in humans, with a biological half-life of 20 to 30 years (Wright & Welbourn, 2002; Landis *et al.*, 2003).

Fish play an important role in human diet, because fishes are rich in omega-3 fatty acids, which are important to maintain balanced levels of blood glucose in the body (Qiu *et al.*, 2011). In addition, it has an important nutrient, due to protein, iodine, different vitamins, minerals and necessary lipid compounds (Vieira *et al.*, 2011). It has a big role in the food chain and is an important marker for many problems in aquatic ecosystems (Aktar *et al.*, 2011). Nevertheless, the contaminated water could have negative effects on the function of the omega-3 fatty

acids and protection human health against heart disease. (Ferreira *et al.*, 2010). Among the many aquatic organisms, fish are considered a good indicator of the effects of pollutants absorbed (Shukla *et al.*, 2007). The process of heavy metals storing in animals' tissue different among animals' types based on the kind of metal (Patnaik *et al.*, 2011). The sublethal concentrations of Cd and lead can bioaccumulate in different tissues, which lead to damage and impaired physiology (Patnaik *et al.*, 2011). The higher bioaccumulation rate was for Cd in fish tissues and many effects on tissue Histology (Vinodhini & Narayanan, 2008). Ebrahimi & Taherianfard (2011) show that the maximum concentrations of Cd in fish tissues were higher than the permissible levels for human consumption. Therefore, the study of fish tissues is an important mechanism to evaluate the health condition of the fish community. (McHugh *et al.*, 2011). Heavy metals toxicity and muscles Histological changes in fishes have been reported by (Mohammed, 2009; Alak *et al.*, 2013b; Begum *et al.*, 2013; Badr *et al.*, 2014).

Planiliza abu is an economically and ecologically important species as well as a human food. It has been detected through the basin of the Euphrates and Tigris rivers, as well as the Mediterranean basin of Southeastern Turkey (Jawad *et al.*, 2015). Therefore, the objective of this study was to evaluate the effects of cadmium toxicity through the sublethal concentrations exposure and effects on Histo-pathological aspects of muscles structures on Juveniles of *P. abu*.

Materials & Methods

Collection and Maintenance

P. abu collected from marine science station aquariums. Fishes were acclimated under laboratory conditions at 23 ± 1 °C and 4 psu

salinity in 10-gallon aquaria (60 X 30 X 30) cm using a 14-h light: 12-h dark photoperiod. The Juveniles mean weight were (10.4-19.8) g and the mean length were (9.6-18.4) cm. Water quality parameters were recorded every day throughout the acclimation period, including water temperature (thermometer) °C, salinity (American Optics Refractometer-psu), dissolved oxygen (YSI Oxygen Meter Model # Quatro Cable Assay, mg.l⁻¹) and pH (pH meter). Juveniles were daily fed Tetramin® Fish Flakes during lab acclimation but, were not fed during acute toxicity tests

Preparing of concentration stock (LC₅₀)

The stock solution was made by solving (6.8466) g of aqueous cadmium sulfate (CdSO₄.8H₂O) in one liter of distilled water that is equal to (1000) ppm. A required weight calculated according to the following equation: Molecular weight of a compound/ Atomic weight of the element = weight of the compound required gm of per liter (gm.l⁻¹).

Calculating the median-lethal concentration

Each aquarium (60 ×30 ×30) cm contained 15 animals with three replicates/ cadmium concentration and controls (n=15 fish/treatment) in each aquarium. Aqueous static renewal tests were conducted to determine 15days LC₅₀ (median lethal concentration) the values concentrations for cadmium under laboratory conditions.

Histo-pathological examination

Parts of skeletal muscles from the control and experimental animals were taken from juveniles exposed to different concentrations of cadmium (0.5,1 and 2) ppm, fixed in Bouin's solution for 48 hrs. and dehydrated in

a graded series of ethyl alcohol (70%, 80%, 90%, 95% and 100%) then cleared in xylene and embedded in paraffin, and sectioned at 5 mm thick. Tissue stained with hematoxylin-eosin method (Humason, 1979) and examined by light microscopy according to Roberts (2001).

Results

Test conditions measured in the cadmium toxicity test are listed in (table 1). After 15days of exposure there were differences in the toxicity of cadmium at all concentrations. Typically, mortality rate increase with increasing cadmium concentrations. For example, the mortality in 0.5, 1 and 2 ppm were (50%,70% and 92%) respectively (table 2). The 15days LC₅₀ of cadmium was 0.405 ppm, (Fig. 1).

Plate (1) shows numerous Histo-pathological alterations in the muscles of *P. abu.* juveniles exposed to different concentrations of cadmium. They are increased gradually with increasing Cd concentration. The pathological findings included marked thickening and hypertrophy in lowest concentration (0.5 ppm) , degeneration along with coagulative necrosis of muscle bundles have been reported in fish exposed to (1 ppm) of Cd . however, muscle tissue showed atrophy, splitting, and separation **with intracellular edema**, at the highest concentration (2 ppm).

Table (1): Water quality conditions measured in cadmium toxicity tests.

Water quality parameter	value measured
Temperature	23 ±1°C
Salinity	4 psu
pH	7.7
Dissolved oxygen	7.50 mg. l ⁻¹

Table (2): Mortality % and LC₅₀ for juveniles *P. abu* exposure to different concentrations of Cadmium (ppm) after 15days of exposure.

Duration	Concentrations (ppm)	Mortality %	LC ₅₀ (ppm)
15-day	0.5	50%	0.405
	1	70%	
	2	92%	

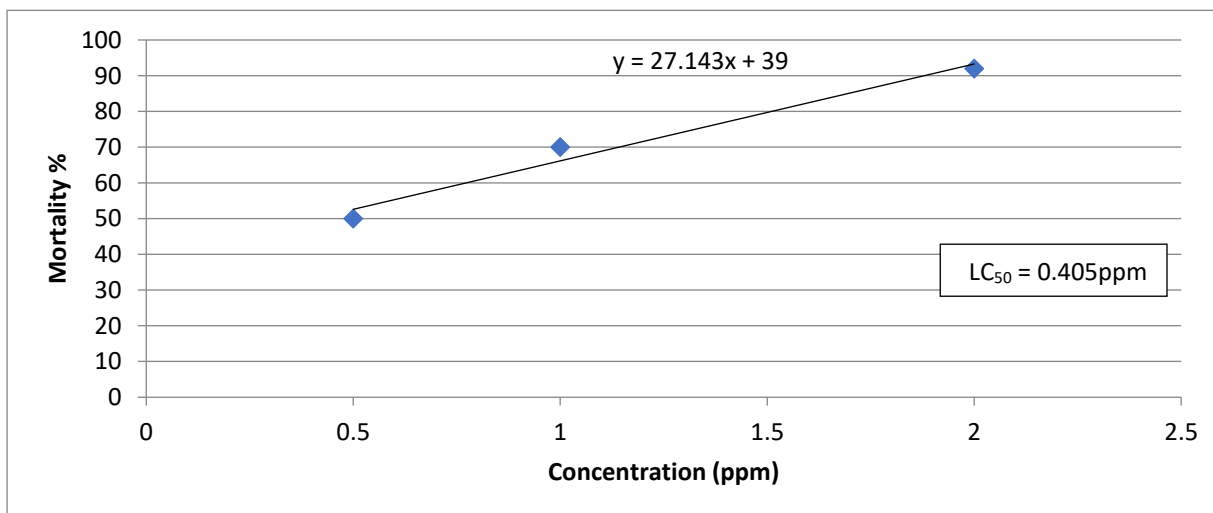


Fig. (1): Mortality percentage of *P. abu* Juveniles exposed to different concentrations after 15 days.

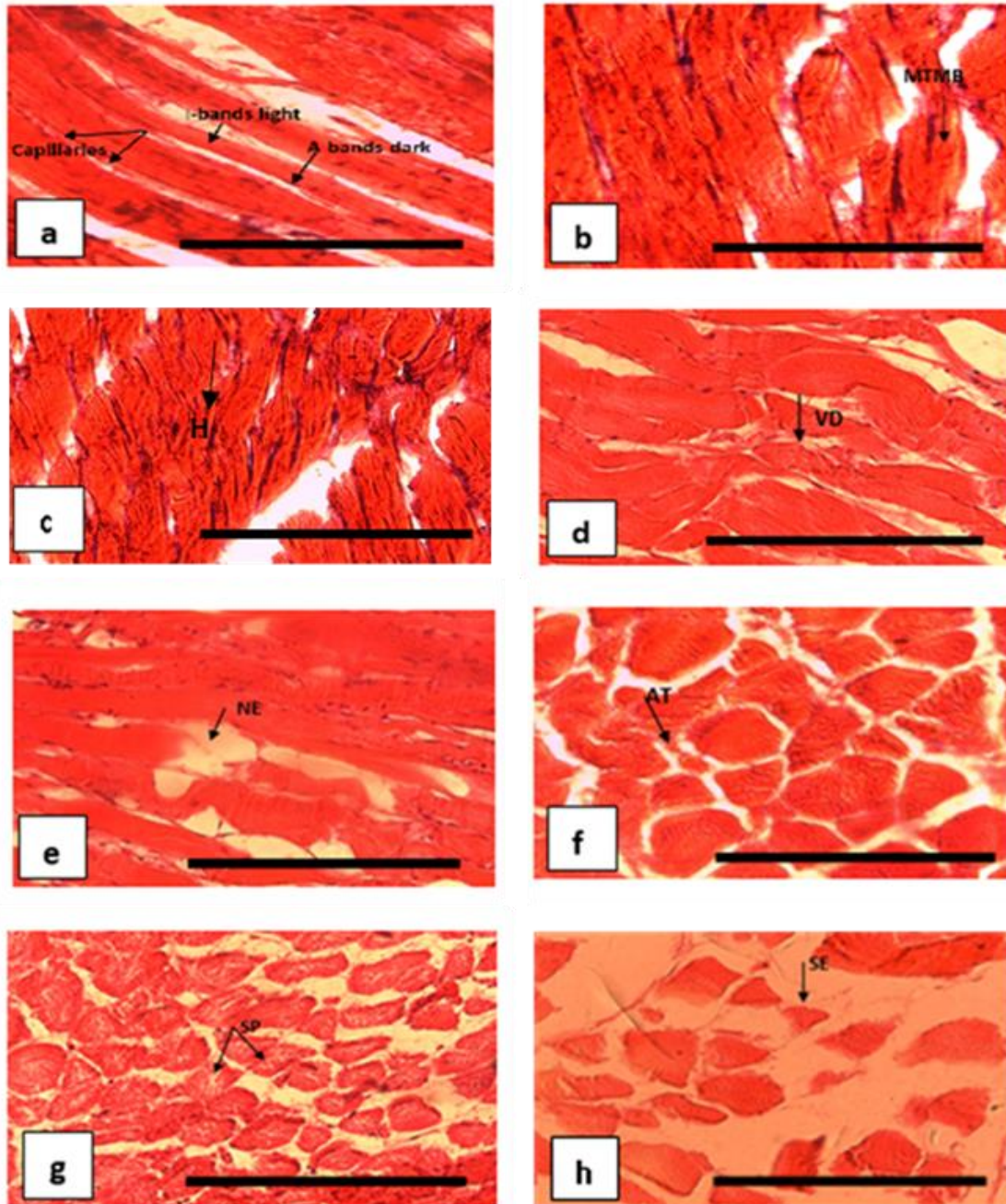


Plate (1): Photomicrograph of the normal structures of the skeletal muscle (Control) of *P. abu* showing; capillaries, bands light and bands dark; (b)& (c) Photomicrographs of muscles (Cadmium treated 0.5) ppm showing; MTMB, marked thickening of muscle bundles , H, hypertrophy; (d),(e), Photomicrographs of muscles (Cadmium treated 1) ppm showing; VD, vacuolar degeneration, NC, coagulative necrosis; (f),(g),(h) Photomicrographs of muscles (Cadmium treated 2) ppm showing; AT, atrophy, SP, splitting, and SE, separation of the muscle bundles with intracellular edema . (H&E). Scale Bar = 40 μ m.

Discussion

The mortality percentage results of *P. abu* juveniles exposed to different concentrations of cadmium (0.5, 1 and 2) ppm were 50%, 70% and 92% respectively (table 2). The 15 days LC₅₀ of cadmium was 0.40 ppm (figure1). This agrees with Hassan (2005) when exposed juvenile of *Carassius carassius* for 14 days to sublethal concentrations of Cd (0.05 & 0.5) ppm the mortality percentage were (70% & 40%) respectively, while the LC₅₀ was (0.35) ppm. Sobha *et al.* (2007) proved that mortality increase over the time, LC₅₀ value of cadmium chloride for the fish *Catla catla* was 4.533 mg.l⁻¹. Hassan (2011) observed the juvenile of common carp *Cyprinus carpio* exposed to sub-lethal concentrations of copper and cadmium (0.1, 0.25, 0.4) ppm led to decreased in survival rate with increasing concentration of copper from 50% to 10% and cadmium from 70% to 20% respectively.

Metals detrimental impact are evident in the environment, aquatic organisms and impairment of the ecological balance systems (Vosyliene & Jankaite, 2006). Moreover, heavy metals could effect on the quality and quantity of fish stocks because of their effects on water quality, physiochemical characteristics and biological components (Mantovi *et al.*, 2005; Singh *et al.*, 2007). Heavy metals have adverse effects on aquatic organism including survival, activity, growth, metabolism and reproduction (Wright & Welbourn, 2002). The aquatic organisms can be exposed to the heavy metals by many routes such as drinking water, eating contaminated sediment and other animals/plants that have been exposed (Wright & Welbourn, 2002). Therefore, fish and other aquatic organism can absorb dissolved metals in water and accumulate in tissues higher than

in water, because metals undergo bioconcentration (Wright & Welbourn, 2002). Heavy metals can accumulate in aquatic organisms including fish tissues more than the water concentration with a range up to 20,000-fold (Popek *et al.*, 2006).

This study examined the Histological changes in fish muscles were increase gradually with Cd concentration including, marked thickening and hypertrophy in lowest concentration (0.5) ppm (plate 1). Exposure to the sublethal concentrations of cadmium recorded number of changes in the muscle's bundles including thickening and intramuscular oedema (Patnaik *et al.*, 2011).

Exposure to the waterborne Cd in aquatic organism causes a significant accumulation of Cd in many organs like muscles (Alak *et al.*, 2013b). Cd can accumulate in the aquatic animals through different routes such as food and water. It then binds to albumins and erythrocytes in blood, which can transfer it into different parts of the body (George *et al.*, 1996; Karadeniz *et al.*, 2009). Damage caused by heavy metals is an important cause of pathological and toxicological processes (Ates *et al.*, 2008). In generally, Histo-pathological studies can be used as an indicator for determining the effects of heavy metals on aquatic organisms. (Bernet *et al.*, 1999; Mohamed, 2009). The Histo-pathological alteration was caused by cadmium poisoning (Alak *et al.*, 2013b).

However, in (1) ppm concentration was showed vacuolar degeneration and necrosis of muscle bundles. The results are in accordance with those obtained by (Mohamed, 2009). Different Histo-logical alterations were observed in the muscles of both fish effects of contaminated drainage water from Lake Qarun, Egypt on *Coptodon zillii* (= *Tilapia zillii*) and *Solea vulgaris.*, which included

vacuolar degeneration and necrosis of muscle bundles. Histo-pathological examinations on the muscles were found at hypodermis of Nile tilapia *Oreochromis niloticus* and which included degeneration (myolysis) and arrangement exposed to different metals (Cu, Zn, Cd and Pb) (Ibrahim *et al.*, 2008). Several Histo-pathological alterations in muscle of two types of fish *O. niloticus* and *Lates. niloticus*, were discovered as a result of the accumulation of metals. One of the Histo-pathological alterations was degeneration in muscle bundles (Mohamed, 2008). Histological examination of *O. niloticus* muscles showed congestion associated with diffuse infiltration with inflammatory cells, hyperactivity of melanomacrophage centers around blood vessels, and focal area of necrosis (Badr *et al.*, 2014).

On the other hand, the highest concentration (2) ppm was showed atrophy, splitting, and separation (plate 2). These results were confirmed with Begum *et al.* (2013) when exposed stinging catfish *Heteropneustes fossilis* exposed to (7.0 and 20.0) ppm of arsenic caused a significant increase in Histo-pathology of muscles bundle such as separation atrophy and splitting. Furthermore, when rainbow trout exposed to different sublethal concentrations (0.18 and 0.35) mg. l⁻¹ of lead caused a significant increase in Histo-pathology in muscles such as myocyte necrosis and atrophy (Alak *et al.*, 2013a). While sublethal concentrations of cadmium caused intramuscular oedema (Patnaik *et al.*, 2011). Brown trout were exposed to 2) ppm of cadmium can cause interstitial mononuclear cell infiltrations in muscle tissues. (Alak *et al.*, 2013b). Some structural changes were observed due to lead acetate exposure, leading to space in muscular bundles and glomerular expansion in *Clarias gariepinus* (Al-Balawi *et al.*, 2013). Exposure

of *Cyprinus carpio*. to sublethal concentrations of cadmium after 28 days of exposure to (1.6) ppm has led to damage in fish muscles tissue Patnaik *et al.*, 2011). After 60 days of exposure, there were partially damaged muscles, and slightly swollen/shortened villi (Begum *et al.*, 2013). According to the Authman *et al.* (2012) exposed Nile tilapia (*O. niloticus*) to different concentrations of metals (Al, Cd, Pb, Hg and Ni), caused various Histo-pathological in muscles bundles.

The concentrations of cadmium in muscular tissue of *O. niloticus* and the concentrations in water, from contaminated fish farms, were (4.354 and 1.315) mg.l⁻¹ respectively (Authman *et al.*, 2012). The order of fishes tissues exposed to different concentrations of Cd were as follows: muscle < gill < liver < heart (Mohamed, 2008). Ibrahim *et al.* (2008) monitors the effects of metals on the biological, Histological and quality aspects of fish. The metals included (Cu, Zn, Cd and Pb) on of fish *O. niloticus* and *C. zillii*. Authman *et al.* (2012) found that heavy metal levels in *O. niloticus* muscles were not possible range of human consumption.

Conclusion

The results were revealed that the mortality increases with increasing cadmium concentrations. Numerous of Histo-pathological changes of *Planiliza abu* Juveniles muscles have been noted. The Histological changes increased with increasing the concentration of the cadmium included, marked thickening and hypertrophy in lowest concentration (0.5 ppm) while atrophy, splitting, and separation, were observed in the tissues of fish muscles bundles at the highest concentration (2) ppm. Future studies should be including testing of

cadmium in different types of aquatic organism.

Acknowledgements

Authors are thankful to the Fisheries and Marine Resources department in Agriculture College of Basrah University for providing laboratory facilities during this study.

References

- Abo El Ella, S. M., Hosny, M. M., & Bakry, M. F. (2005). Utilizing fish and aquatic weeds infestation as bioindicators for water pollution in Lake Nubia, Sudan. *Egyptian Journal of Aquatic Biology and Fisheries*, 9: 63-84. <http://dx.doi.org/10.12944/CWE.7.2.15>
- Alak, G., Atamanalp, M., Topal, A., Arslan, H., Kocaman, E. M., & Oruç, E. (2013a). Effect of sub-lethal lead toxicity on the histopathological and antioxidant enzyme activity of rainbow trout (*Oncorhynchus mykiss*). *Fresenius Environmental Bulletin*, 22(5), 733-738. https://www.researchgate.net/profile/Gonca_Alak/publication/316113119.
- Alak, G., Atamanalp, M., Topal, A., Arslan, H., Oruç, E., & Altun, S. (2013b). Histopathological and biochemical effects of humic acid against cadmium toxicity in brown trout gills and muscles. *Turkish Journal of Fisheries and Aquatic Sciences*, 13(2), 315-320. <https://www.researchgate.net/publication/270338180>.
- Al-Balawi, H. F. A., Al-Akel, A. S., Al-Misned, F., Suliman, E. A. M., Al-Ghanim, K. A., Mahboob, S., & Ahmad, Z. (2013). Effects of sub-lethal exposure of lead acetate on histopathology of gills, liver, kidney and muscle and its accumulation in these organs of *Clarias gariepinus*. *Brazilian Archives of Biology and Technology*, 56, 293-302. <https://doi.org/10.1590/S1516-89132013000200015>
- Aktar, M. W., Sengupta, D., & Chowdhury, A. (2011). Occurrence of heavy metals in fish: a study for impact assessment in industry prone aquatic environment around Kolkata in India. *Environmental Monitoring and Assessment*, 181, 51-61. <https://link.springer.com/article/10.1007/s10661-010-1812-x>
- Amdur, M.O., Doull, J., Curtis, M.D. & Kloasen, C.D. (1992). *Cassarett and Doull's Toxicology. Pergamon: The Basic Science of Poisons*. New York/Oxford. (p. 996). https://doi.org/10.7326/0003-4819-117-5-448_2
- Ates, B., Orun, I., Talas, Z. S., Durmaz, G., & Yilmaz, I. (2008). Effects of sodium selenite on some biochemical and hematological parameters of rainbow trout (*Oncorhynchus mykiss* Walbaum, 1792) exposed to Pb²⁺ and Cu²⁺. *Fish Physiology and Biochemistry*, 34(1), 53-59. <https://link.springer.com/article/10.1007%2Fs10695-007-9146-5>
- Authman, M. M., Abbas, W. T., & Gaafar, A. Y. (2012). Metals concentrations in Nile tilapia *Oreochromis niloticus* from illegal fish farm in Al-Minufiya Province, Egypt, and their effects on some tissues structures. *Ecotoxicology and Environmental Safety*, 84, 163-172. <https://doi.org/10.1016/j.ecoenv.2012.07.005>
- Badr, A. M., Mahana, N. A., & Eissa, A. (2014). Assessment of heavy metal levels in water and their toxicity in some tissues of Nile Tilapia (*Oreochromis niloticus*) in River Nile basin at Greater Cairo, Egypt. *Global Veterinaria*, 13(4), 432-443. <https://doi.org/10.5829/idosi.gv.2014.13.04.8561>
- Bai, L. Y., Zeng, X. B., Li, L. F., Chang, P. E. N., & Li, S. H. (2010). Effects of land use on heavy metal accumulation in soils and sources analysis. *Agricultural Sciences in China*, 9(11), 1650-1658. [https://doi.org/10.1016/S1671-2927\(09\)60262-5](https://doi.org/10.1016/S1671-2927(09)60262-5)
- Begum, A., Mustafa, A. I., Amin, M. N., Banu, N., & Chowdhury, T. R. (2013). Accumulation and histopathological effects of arsenic in tissues of shingi fish (Stinging Catfish) *Heteropneustes fossilis* (Bloch, 1794). *Journal of the Asiatic Society of Bangladesh, Science*, 39, 221-230. <https://www.banglajol.info/index.php/JASBS/article/view/17861>
- Bernet, D., Schmidt, H., Meier, W., Burkhardt-Holm, P., & Wahli, T. (1999). Histopathology in fish: proposal for a protocol to assess aquatic pollution. *Journal of Fish Diseases*, 22, 25-34. <https://doi.org/10.1046/j.1365-2761.1999.00134.x>
- Beširović, H., Alić, A., Prašović, S., & Drommer, W. (2010). Histopathological effects of chronic exposure to cadmium and zinc on kidneys and gills of brown trout (*Salmo trutta* morph. *fario*). *Turkish*

Journal of Fisheries and Aquatic Sciences, 10, 255-262. <https://doi.org/10.4194/trjfas.2010.0214>

- Biswas, S., Prabhu, R. K., Hussain, K. J., Selvanayagam, M., & Satpathy, K. K. (2012). Heavy metals concentration in edible fishes from coastal region of Kalpakkam, southeastern part of India. *Environmental Monitoring and Assessment*, 184, 5097-5104. <https://link.springer.com/article/10.1007/s10661-011-2325-y>
- Bradl, H. (Ed.). (2005). *Heavy Metals in the Environment: Origin, Interaction and Remediation*. Elsevier. Volume 6, Academic Press, 282pp. <https://www.elsevier.com/books/heavy-metals-in-the-environment-origin-interaction-and-remediation/bradl/978-0-12-088381-3>
- Ceyhun, S. B., Şentürk, M., Yerlikaya, E., Erdoğan, O., Küfrevioglu, Ö. İ., & Ekinci, D. (2011). Purification and characterization of carbonic anhydrase from the teleost fish *Dicentrarchus labrax* (European seabass) liver and toxicological effects of metals on enzyme activity. *Environmental Toxicology and Pharmacology*, 32, 69-74. <https://doi.org/10.1016/j.etap.2011.03.013>
- Das, B. K., & Mukherjee, S. C. (2000). A histopathological study of carp (*Labeo rohita*) exposed to hexachlorocyclohexane. *Veterinarski Arhiv*, 70, 169-180. <http://www-staro.vet.unizg.hr/vetarhiv/papers/70-4/das.pdf>
- Ebrahimi, M. & Taherianfard, M. (2011). The effects of heavy metals exposure on reproductive systems of cyprinid fish from Kor River. *Iranian Journal of Fisheries Sciences*, 10, 13-26. <http://jifro.ir/article-1-121-en.html>
- Ferreira, M., Caetano, M., Antunes, P., Costa, J., Gil, O., Bandarra, N. & Reis-Henriques, M. A. (2010). Assessment of contaminants and biomarkers of exposure in wild and farmed sea bass. *Ecotoxicology and Environmental Safety*, 73, 579-588. <https://doi.org/10.1016/j.ecoenv.2010.01.019>
- George, S. G., Todd, K. & Wright, J. (1996). Regulation of metallothionein in teleosts: induction of MTmRNA and protein by cadmium in hepatic and extrahepatic tissues of a marine flatfish, the turbot (*Scophthalmus maximus*). *Comparative Biochemistry and Physiology Part C: Pharmacology, Toxicology and Endocrinology*, 113, 109-115. [https://doi.org/10.1016/0742-8413\(95\)02076-4](https://doi.org/10.1016/0742-8413(95)02076-4)
- Hassan, B. K. (2005). *The Effect of Sub Lethal Concentration of Cadmium on Gill and Liver of Carassian carp Carassius carassius (L.)*. M. Sc. Thesis, College of Agriculture, University of Basrah, 53pp. (In Arabic). link.springer.com/article/10.1007/s40011-016-0806-z
- Hassan, B. K. (2011). The effect of copper and cadmium on oxygen consumption of the juvenile common carp, *Cyprinus carpio* (L.). *Mesopotamian Journal of Marine Science*, 26, 25-34. DOI:10.21276/mjms
- Humason, G. L. (1979). *Animal Tissue Techniques*. 4th edition, W.H. Freeman and company, San Francisco, CA, 661pp. <https://www.abebooks.com/book-search/isbn/9780716702993/>
- Ibrahim, S. M., Shalloof, K. A., & Salama, H. M. (2008). Effect of environmental conditions of Abu-Zabal Lake on some biological, histological and quality aspects of fish. *Global Veterinaria*, 2, 257-270. <https://www.researchgate.net/publication/237278271>
- Jawad, L., Bobori, D., Al-Shwikh, H., & Al-Saleh, F. (2015). Opercular girth, maximum girth and total length relationships for *Planiliza abu* (Heckel, 1843) and *Chondrostoma regium* (Heckel, 1843) (Actinoprerygii) from Euphrates River at Dier Ez-Zor Governorate, Syria. *Acta Zoologica. Bulgaria*, 67, <http://acta-zoologica-bulgarica.eu/downloads/acta-zoologica-bulgarica/2015/67-4-591-594.pdf>
- Karadeniz, A., Cemek, M., & Simsek, N. (2009). The effects of *Panax ginseng* and *Spirulina platensis* on hepatotoxicity induced by cadmium in rats. *Ecotoxicology and Environmental Safety*, 72, 231-235. <https://doi.org/10.1016/j.ecoenv.2008.02.021>
- Landis, W., Sofield, R., Yu, M. H. & Landis, W. G. (2003). *Introduction to Environmental Toxicology Impacts of Chemicals Upon Ecological Systems*. Third edition, CRC Press, 512pp. https://books.google.iq/books/about/Introduction_to_Environmental_Toxicology.html?id=PNtC_Z7P8YC&redir_esc=y
- Mantovi, P., Baldoni, G., & Toderi, G. (2005). Reuse of liquid, dewatered, and composted sewage sludge on agricultural land: effects of long-term application on soil and crop. *Water Research*, 39,

- 289-296.
<https://doi.org/10.1016/j.watres.2004.10.003>
- McHugh, K. J., Smit, N. J., Van Vuren, J. H. J., Van Dyk, J. C., Bervoets, L., Covaci, A., & Wepener, V. (2011). A histology-based fish health assessment of the tigerfish, *Hydrocynus vittatus* from a DDT-affected area. *Physics and Chemistry of the Earth, Parts A/B/C*, 36, 895-904.
<https://doi.org/10.1016/j.pce.2011.07.077>
- Mohamed, F. A. (2008). Bioaccumulation of selected metals and histopathological alterations in tissues of *Oreochromis niloticus* and *Lates niloticus* from Lake Nasser, Egypt. *Global Veterinaria*, 2, 205-218.
<http://citeseerx.ist.psu.edu/viewdoc/download?doi=10.1.1.499.3845&rep=rep1&type=pdf>
- Mohamed, F. A. (2009). Histopathological studies on *Tilapia zillii* and *Solea vulgaris* from Lake Qarun, Egypt. *World Journal of Fish and Marine Sciences*, 1, 29-39.
<http://citeseerx.ist.psu.edu/viewdoc/download?doi=10.1.1.533.5081&rep=rep1&type=pdf>
- Patnaik, B. B., Howrelia, H., Mathews, T., & Selvanayagam, M. (2011). Histopathology of gill, liver, muscle and brain of *Cyprinus carpio communis* L. exposed to sublethal concentration of lead and cadmium. *African Journal of Biotechnology*, 10, 12218-12223.
<https://www.ajol.info/index.php/ajb/article/view/96295>
- Popek, W., Dietrich, G., Glogowski, J., Demska-Zakeś, K., Drag-Kozak, E., Sionkowski, J., Łuszczek-Trojan, E., Epler, P., Demianowicz, W., Sarosiek, B., Kowalski, R., Jankun, M., Zakeś, Z., Król, J., Czerniak, S., & Szczepkowski, M. (2006). Influence of heavy metals and 4-nonylphenol on reproductive function in fish. *Reproductive Biology*, 6, 175-188.
<https://europemc.org/article/med/16967097>
- Qiu, Y. W., Lin, D., Liu, J. Q., & Zeng, E. Y. (2011). Bioaccumulation of trace metals in farmed fish from South China and potential risk assessment. *Ecotoxicology and Environmental Safety*, 74, 284-293.
<https://doi.org/10.1016/j.ecoenv.2010.10.008>
- Raissy, M., Ansari, M., & Rahimi, E. (2011). Mercury, arsenic, cadmium and lead in lobster (*Panulirus homarus*) from the Persian Gulf. *Toxicology and Industrial Health*, 27, 655-659.
<https://doi.org/10.1177/0748233710395346>
- Roberts, R. J. (2001). *Fish Pathology*, Third edition. W. B. Saunders, Philadelphia, PA, 462pp.
<https://www.worldcat.org/title/fish-pathology/oclc/45313495>
- Shukla, V., Dhankhar, M., Prakash, J., & Sastry, K. V. (2007). Bioaccumulation of Zn, Cu and Cd in *Channa punctatus*. *Journal of Environmental Biology*, 28, 395.
http://www.jeb.co.in/journal_issues/200704_apr07_supp/paper_07.pdf
- Singh, R. K., Chavan, S. L., & Sapkale, P. H. (2007). Heavy metal concentrations in water, sediments and body tissues of red worm (*Tubifex* spp.) collected from natural habitat *Toxicology & Pharmacology*, 147(2), 168-178.s in Mumbai, India. *Environmental Monitoring and Assessment*, 129, 471-481.
<https://doi.org/10.1007/s10661-006-9377-4>
- Soares, S. S., Martins, H., Gutiérrez-Merino, C., & Aureliano, M. (2008). Vanadium and cadmium in vivo effects in teleost cardiac muscle: metal accumulation and oxidative stress markers. *Comparative Biochemistry and Physiology Part C: Toxicology & Pharmacology*, 147, 168-178.
<https://doi.org/10.1016/j.cbpc.2007.09.003>
- Sobha, K., Poornima, A., Harini, P., & Veeraiah, K. (2007). A study on biochemical changes in the freshwater fish, *Catla catla* (Hamilton) exposed to the heavy metal toxicant cadmium chloride. *Kathmandu University Journal of Science, Engineering and Technology*, 3, 1-11.
<https://doi.org/10.3126/kuset.v3i2.2890>
- Taylor, M. D. (1997). Accumulation of cadmium derived from fertilizers in New Zealand soils. *Science of the Total Environment*, 208(1-2), 123-126. [https://doi.org/10.1016/S0048-9697\(97\)00273-8](https://doi.org/10.1016/S0048-9697(97)00273-8)
- Vieira, C., Morais, S., Ramos, S., Delerue-Matos, C., & Oliveira, M. B. P. P. (2011). Mercury, cadmium, lead and arsenic levels in three pelagic fish species from the Atlantic Ocean: Intra-and inter-specific variability and human health risks for consumption. *Food and Chemical Toxicology*, 49, 923-932.
<https://doi.org/10.1016/j.fct.2010.12.016>
- Vinodhini, R., & Narayanan, M. (2008). Bioaccumulation of heavy metals in organs of freshwater fish *Cyprinus carpio* (Common carp). *International Journal of Environmental Science &*

Technology, 5, 179-182.
<https://link.springer.com/article/10.1007%252FBF03326011>

Vosylienè, M. Z., & Jankaitè, A. (2006). Effect of heavy metal model mixture on rainbow trout biological parameters. *Ekologija*, 4, 12-17.
<https://vb.gamtc.lt/object/elaba:6213167/>

Wright, D. A., & Welbourn, P. (2002). *Environmental Toxicology* (Vol. 11). Cambridge University Press, 630pp.

https://books.google.iq/books/about/Environmental_Toxicology.html?id=F8y12B3gIbkC&redir_esc=y

تأثير التراكيز تحت المميتة للكادميوم على التغيرات المرضية النسيجية لعضلات يافعات اسماك الخشني *Planiliza abu* (Heckel, 1843)

انتصار شعبان هاشم و رجاء نوري الياسين

قسم الاسماك والثروة البحرية، كلية الزراعة، جامعة البصرة، العراق

المستخلص: تلوث المياه بالمعادن قضية عالمية، بسبب تأثيره الضار على البيئة والكائنات المائية وضعف نظم التوازن البيئي. الكادميوم معدن ثقيل شديد السمية ، حتى في الجرعات المنخفضة ، وبالتالي فهو مصدر قلق كبير للنظام البيئي. يمكن أن يسبب الكادميوم العديد من التغيرات المرضية في الأعضاء المختلفة في الأسماك. بينت هذه الدراسة آثار التراكيز تحت المميتة لسمية الكادميوم وآثارها على الأنسجة المرضية للأنسجة العضلية على يافعات الخشني *Planiliza abu*. كانت تراكيز الكادميوم تتراوح من 0.5-2 جزء في المليون لمدة 15 يوماً من التعرض. بلغ التركيز النصف المميت LC_{50} (0.40 جزء في المليون). لوحظ أن العديد من التغيرات النسيجية زادت بشكل تدريجي مع تركيز الكادميوم، بما في ذلك سماكة ملحوظة وتضخم في أقل تركيز (0.5 جزء في المليون). بينما في أعلى تركيز (2 جزء في المليون)، كانت الأنسجة المرضية ضموراً ، انشقاقاً ، وانفصالاً ، في حزم عضلات.

الكلمات المفتاحية: الخشني *Planiliza abu*، الكادميوم، تراكيز تحت المميتة. عضلات، أمراض نسيجية.