

Histopathological Changes in the Liver and Spleen of Common Carp *Cyprinus carpio* L. Challenge with *Pseudomonas aeruginosa* (Schroeter, 1872) Fed with Dietary Chitosan and Ciprofloxacin

Omeed F.M.H Al-Mossawai^{1*} & Atheer H. Ali²

¹Department of Pathology and Poultry Diseases, College of Veterinary Medicine, University of Basrah, Iraq

²Department of Fisheries and Marine Resources, College of Agriculture, University of Basrah, Iraq

*Corresponding author E-mail: omeetomeet7@gmail.com

Received 19 September 2019; Accepted 18 November 2019; Available online 31 December 2019

Abstract: The current study was conducted for 90 days in order to study the efficacy of dietary chitosan and antibiotic ciprofloxacin supplement as a resistance and presentation of fishes against the bacteria (*Pseudomonas aeruginosa*) by effect on liver and spleen of fishes. The fishes were divided into four categories of groups at two periods; the former at infection (at 90th day of feeding period) and the latter at post infection (14 days after the challenge period). The first and second groups (T1 and T2) were considered as negative and positive controls (both fed on standard diet), respectively, while the third and fourth groups (T3 and T4) represent dietary chitosan and dietary antibiotic supplement, respectively. All groups, except T1, were challenged by bacteria at 90th day of feeding period. Liver of positive control revealed severe degeneration, especially around hepatic vein with congestion and fibrosis, while the spleen exhibited haemorrhage, lymphocytosis and lymphatic accumulation of white pulp with hemosiderin. The histopathological changes in liver of chitosan group at the infection period were characterized by vacuolation, inflammatory cells and hemorrhage, while necrosis and swelling of hepatocytes and infiltration with inflammatory cells at post infection period. The spleen at the infection period was suffered from leukocytosis, accumulation of inflammatory cells and macrophages, presence of focus from phagocytic macrophages. The liver in antibiotic group of infection period displayed narrowing of the sinusoid, swelling of hepatocytes and infiltration with inflammatory cells, hyperplasia in the bile duct, while the abnormal accumulation of lymphatic follicles. At postinfection period, the spleen showed thickness at the wall capsule, presence of homogeneous pinkish matter around arteriole in the red pulp and lymphocytosis in the white pulp. The supplemented chitosan groups showed a significant decrease in the mortality percentage ($p \leq 0.01$). The supplemented chitosan groups showed a significant decrease in the mortality percentage. $p \leq 0.01$.

Keywords: Fish, Cyprinidae, Bacteria, *Pseudomonas*, Chitosan, Antibiotic.

Introduction

Pseudomonas aeruginosa is a flagellated Gram-negative opportunistic pathogen of plants and animals, and is found naturally in

soil and water (Phennicie *et al.*, 2010). It is a zoonotic bacterium (Austin & Austin, 2007) responsible for high mortality in fish hatchery worldwide (Amrevuawho *et al.*, 2014). *P.*

aeruginosa revealed a high degree of global antibiotic resistance (Rocchetta *et al.*, 1999), making infections by this bacterium a serious concern to hospital-bound patients. Myriad virulence factors carried by this bacterium afford *P. aeruginosa* the ability to infect a broad range of species (Clatworthy *et al.*, 2009).

The treatment of fishes is economically costly and the success effect is not guaranteed. Therefore, the occurrence of an epidemic disease in a fish pond or farm may result in the loss of all or most of the fishes. Consequently, emphasis should be placed on prevention operations in the first place. This is exposed to various diseases, especially bacterial diseases. To control these diseases, usage of antibiotics for the purpose of prevention before the onset of signs of disease or treatment when the disease appears is recommended (Manage, 2018). Many fish farmers use antibiotics in their farms, which is a very dangerous when concentrated in the bodies of fishes, and transmitted to humans after which leads to the occurrence of immunity against antibiotics in the human body, and if human exposure to diseases occurs, the use of these antibiotics is useless and ultimately destroys human health (Pham *et al.*, 2015).

The use of antibiotics in aquaculture causes selective pressures resulting in quantities of bacterial resistance and transportable resistance genes in fish pathogens and other bacteria in the aquatic environment. Bacteria in the aquatic environment can spread by transferring genes and reaching human pathogens. The risk of transmission of genes from fish pathogens and other bacteria in the aquatic environment to human pathogens has not been fully investigated at risk of transmission of genes from fish pathogens

and other bacteria in the aquatic environment to human pathogens. (Koh *et al.*, 2016; Watts *et al.*, 2017).

Raise critical issues regarding the use of antibiotics in aquaculture according to their negative or collateral effects on aquaculture species and aquatic ecosystems revealed that the majority of antibiotics given to fishes were actually metabolized after ingestion, but were excreted by urine or faeces without complete decomposition, and hence the remaining concentrations in the water system have negative effects including environmental pollution, degradation of aquatic ecosystems and resistance to drug pathogens (Iheanacho *et al.*, 2017).

Owing to extensive use of therapeutic agents in aquaculture, the emergence of antimicrobial resistance has been documented between pathogens and associated environmental hazards, thus, many alternative strategies have been proposed such as the use of different immunostimulants (stimuli). The use of immunostimulants for fishes can improve the resistance of fishes against unfavourable environmental conditions and pathogenic factors compared to other treatments. (Meshkini *et al.*, 2012).

Chitosan has important biological characters, harbour vast advantages in wide applications in food, biomedicine, chemo medicine and industrial applications. So, its action is similar to fibre and does not cause any intestinal damage in case of undigestion in the intestine due to absence of decomposing enzymes e.g. Chitonase. Therefore, it will be like food fibres without any problems in the gut (Iheanacho *et al.*, 2017).

Certain studies exhibited that the addition of chitosan to the diet gave positive affects in the immune response and the survival rate of common carp, and the addition of 2% dietary chitosan can enhance the immunity response against bacterial infection and reduce the mortality of fishes under stress conditions (Maqsood *et al.*, 2002; Lin *et al.*, 2012; Alishahi *et al.*, 2014), including those on mariculture (Harikrishnan *et al.*, 2012).

In Iraq, no previous studies on use of chitosan as a dietary supplement in diet of fishes were done, except that of Mustafa *et al.* (2014) which was conducted to assess the effect of adding different concentrations of chitosan to the diet on immune response and survival rate of the common carp after a challenge with *Aeromonas hydrophila*. There was a significant increase ($P < 0.05$) in immunity criteria (chitosan 2%) in comparison to control and other groups (0.75 and 1.5%), higher growth rates and the effectiveness of lysozyme enzyme.

The aim of the present study is to evaluate the efficacy of dietary chitosan supplement as resistance material against the bacteria (*P. aeruginosa*) on liver and spleen and compare it with that of dietary antibiotic group at infection (at 90th day of feeding period) and post infection (two weeks after the challenge).

Materials & Methods

Fish specimens of the study

A total of 180 live common carps weighing 13.5-17.7 g were obtained from ponds of Marine Science Centre, University of Basrah and transported to the laboratory of Fish Diseases and Parasitology, Department of Fisheries and Marine Resources, College of Agriculture, University of Basrah during 29 November 2018. The fishes were sterilized in a saturated saline solution to get rid of

pathogens and ectoparasites. They were acclimated for 14 days and fed on a standard diet. Fishes were randomly distributed in 18 tanks: 7-8 fishes per tank of 50 litre. Water quality criteria were controlled by measuring daily temperature of $24.25 \pm 0.67^\circ \text{C}$, salinity of $2.3 \pm 0.21 \text{ PSU}$, pH 7.44 ± 0.14 and dissolved oxygen 6.93 ± 0.45 .

Diet preparation

Three different types of diet were prepared the basal (control), chitosan and antibiotic diets, to compare the effect of supplement chitosan or ciprofloxacin to diet for verifying the activity of chitosan and ciprofloxacin as antibacterial and resistance material against the infection with *P. aeruginosa*. Each supplement component was added to the basal group (control) separately. Commercial chitosan powder (Mystic motinent) was added to the basal diet by 2% diet weight (Mustafa *et al.*, 2014), while ciprofloxacin powder was added with 0.02% diet weight (Flores-Miranda *et al.*, 2012).

P. aeruginosa activation

The 24 hrs. bacterial culture was attended by taking a swab from the original culture (stock culture) of the bacteria by the loop mineral carrier and placed in a test tube containing the sterile Nutrient Broth (N.B.) feed medium. Pipes were incubated at 37°C for 24 hrs. To confirm diagnosis of the bacteria, *Pseudomonas* Isolation Agar (PIA) was used after autoclave sterilization and poured into Petri dishes taken from the pre-equipped 0.1 ml from the 24 hrs. bacterial culture spread on the bacterial culture medium and incubated for 24 hrs. at 37°C . At the onset of growth, a gram of bacterial culture was stained and microscopically diagnosed, and examine the growing colonies in the dish in terms of shape, colour, edge and appearance (Harley & Prescott, 2002). *P. aeruginosa* was challenged

in NB 37° C for 24 hrs., then compared with standard McFarland's tubes that were prepared according to Garvey *et al.* (1977). The reading was taken by the optical spectrometer with a wavelength of 600 nm. The bacterial suspension of *P. aeruginosa* was compared with the McFarland reading. Any observation of turbidity is equal when the two readings mean that the number of bacteria became 10⁸ ml⁻¹.

Challenge the fishes with *P. aeruginosa*

After 90 days of the feeding period, the fishes were prepared to the challenge with 1×10⁷ CFU ml⁻¹ by using intraperitoneal injection, where each fish individual received 0.1 ml of bacterial solution. Physiological saline was used in the injection for the control specimens. After infection, the animals were observed for two weeks. At this period, any external or internal symptoms on the fishes were analysed, and subsequently the challenge and the mortality was counted during the period.

The percentage mortality in each of the experimental group was recorded up to the 90th day after challenge. The percentage of mortality was calculated by using the following equation:

$$\text{Mortality \%} = \left(\frac{\text{Number of fish died after challenge}}{\text{Initial number of fish}} \right) \times 100$$

Statistical analysis

The data were analysed by using one-way ANOVA, SPSS V.16. The means of the studied mortality percentages were compared by using Duncan's multiple range tests to find the differences.

Histopathological study

Liver and spleen from different fish groups were isolated, fixed in 10% buffered formalin, sectioned at 7µm thickness and stained with Harris haematoxylin- Eosin (Humason, 1972).

Results

Percentage of fish mortality

The two dietary chitosan groups (T3 and T4) and antibiotic group (T5) exhibited low mortality percentages (12.29%, 19.03% and 25.08%, respectively) in comparison with the control group (43.61%) as indicated in fig. (1).

Histological effect of dietary chitosan on fish liver and spleen challenged with *P. aeruginosa*

Plate (1) showed the histological section of a normal liver of negative control and chitosan groups after 90 days. Plate (1a) revealed normal liver, while plates (3b & 3c) indicated the liver of fishes which were fed with dietary chitosan after their challenge with the bacteria. The pathological changes represented swelling of hepatocytes (yellow arrow) and presence of both inflammatory cells (black arrow) and necrosis of hepatic cells (blue arrow).

Plate (2a) presented normal structure of the liver and bile duct (arrow head), whereas plates (2b & 2c) demonstrated the liver of chitosan groups with vacuoles, degeneration and occurrence of inflammatory cells (yellow arrow), and the haemorrhage (blue arrow) due to presence of haemoglobin. The haemorrhage was also noted in the spleen (Plate 3, yellow arrow) with distributed of lymphoid accumulation of white pulp.

Plate (3) demonstrated the infected spleen with *P. aeruginosa* in positive control groups. mild haemorrhage (yellow arrow) with lymphoid accumulation at white pulp and the presence of hemosiderin (blue arrow) and lymphocytosis (green arrow) is clear. Plate (4) showed infected spleen with *P. aeruginosa* in chitosan group. It indicated the effect of dietary chitosan in increasing of defence

leucocytes (leucocytosis, yellow arrow) and infiltration of inflammatory cells around blood vessel (red arrow), while plate (5) revealed the accumulation of macrophages

and degeneration (blue arrow) as well as the presence of focus from phagocytic

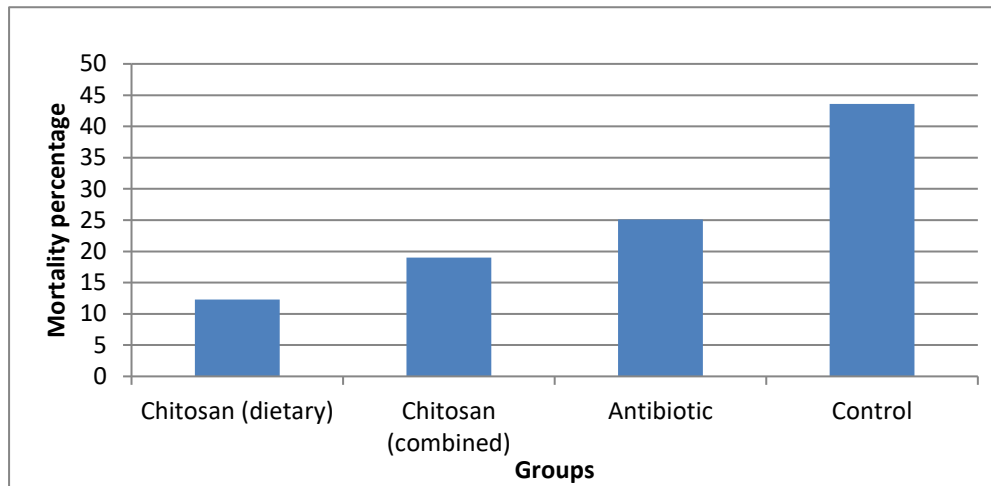


Fig. (1): Percentage of mortality (%) of *C. carpio* fed with basal, chitosan-supplemented or antibiotic diet.

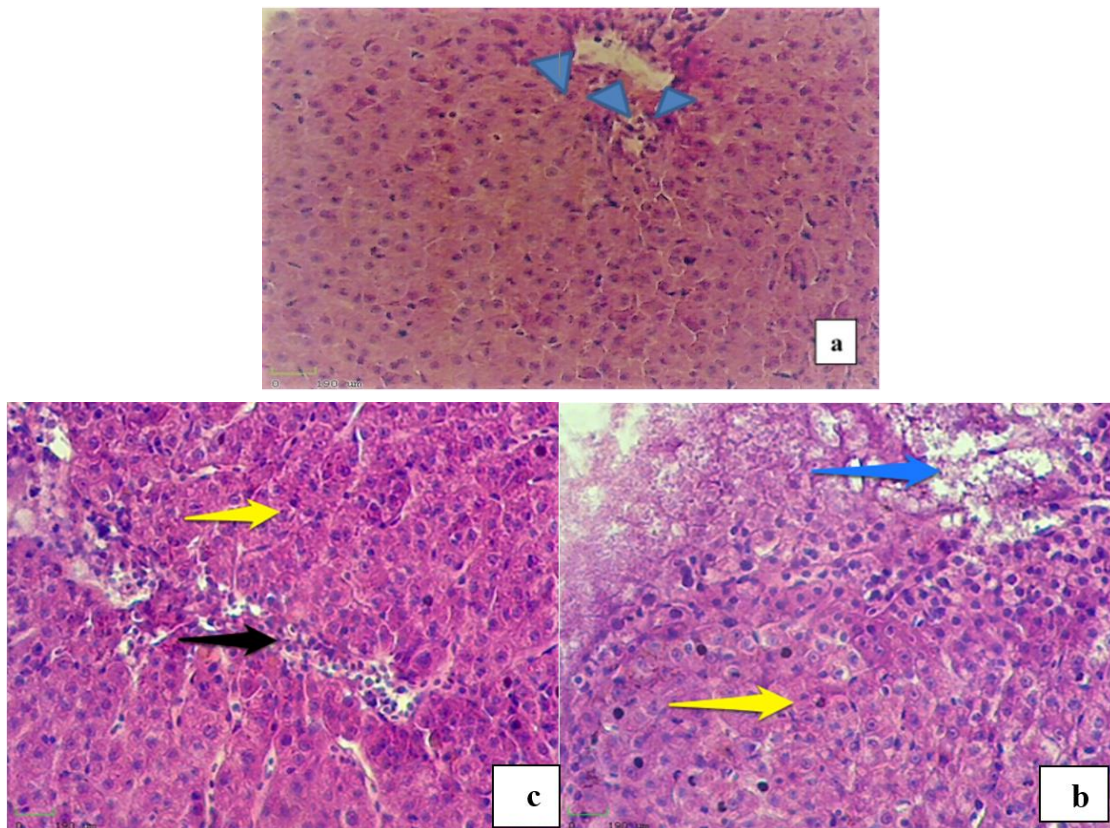


Plate (1): a- Histological section of liver of negative control, b and c- Histological section of liver of fish challenged with *P. aeruginosa*. (400×). Hepatic arteriole (arrow head), necrosis (blue arrow) near and inflammatory cells area (black arrow), swelling of hepatocytes (yellow arrow). (H & E, 400x).

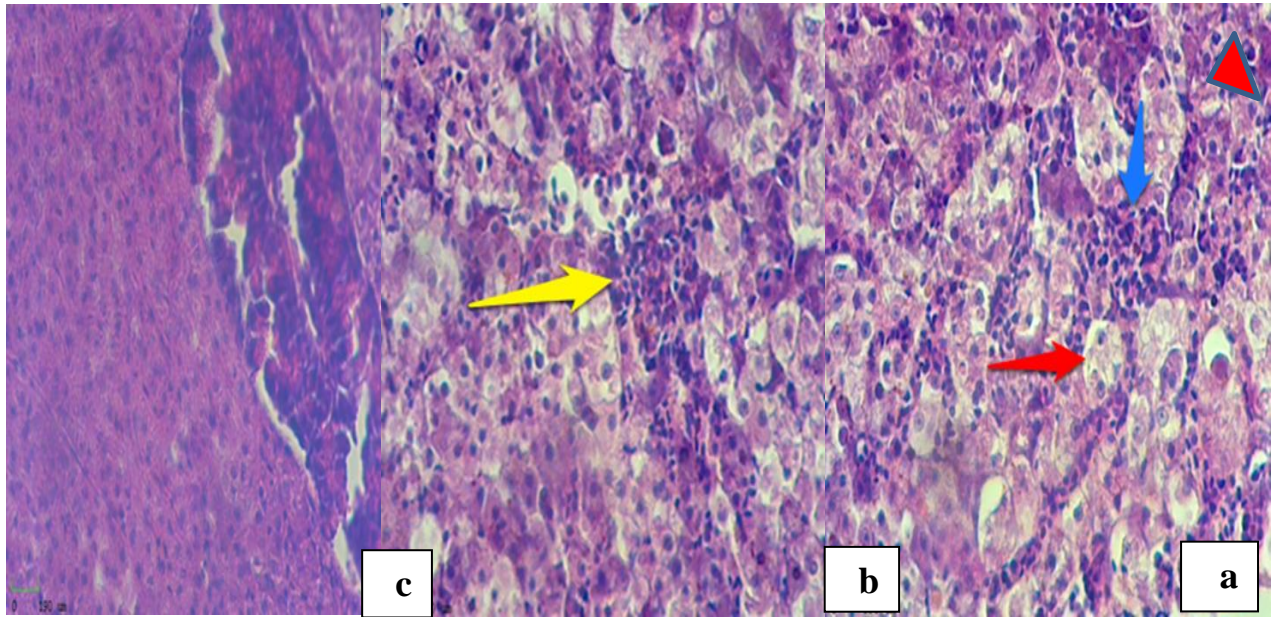


Plate (2): a- Normal liver, b & c-infected liver with *P. aeruginosa* at 90th day (400x). Bile duct (arrow head), inflammatory cells (yellow arrow), vacuolation (red arrow) and haemorrhage (blue arrow). (H & E, 400x).

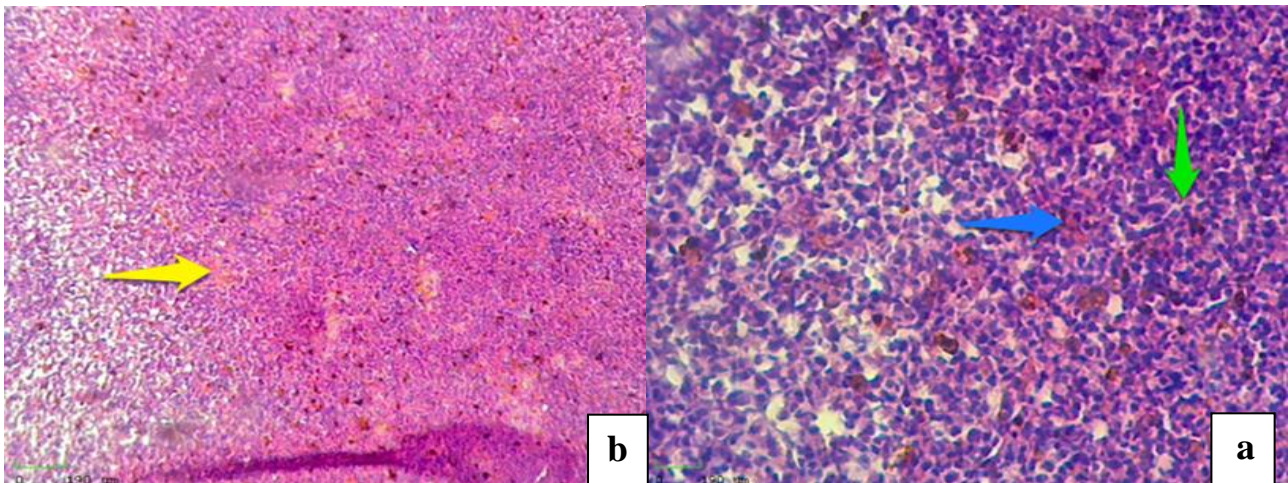


Plate (3): a- Spleen after the infection with *P. aeruginosa*, b- the same in high magnification. Note the mild haemorrhage (yellow arrow) with lymphatic accumulation of white pulp with shiny area represent hemosiderin (blue arrow) and lymphocytosis (light green arrow). (H & E, 400x).

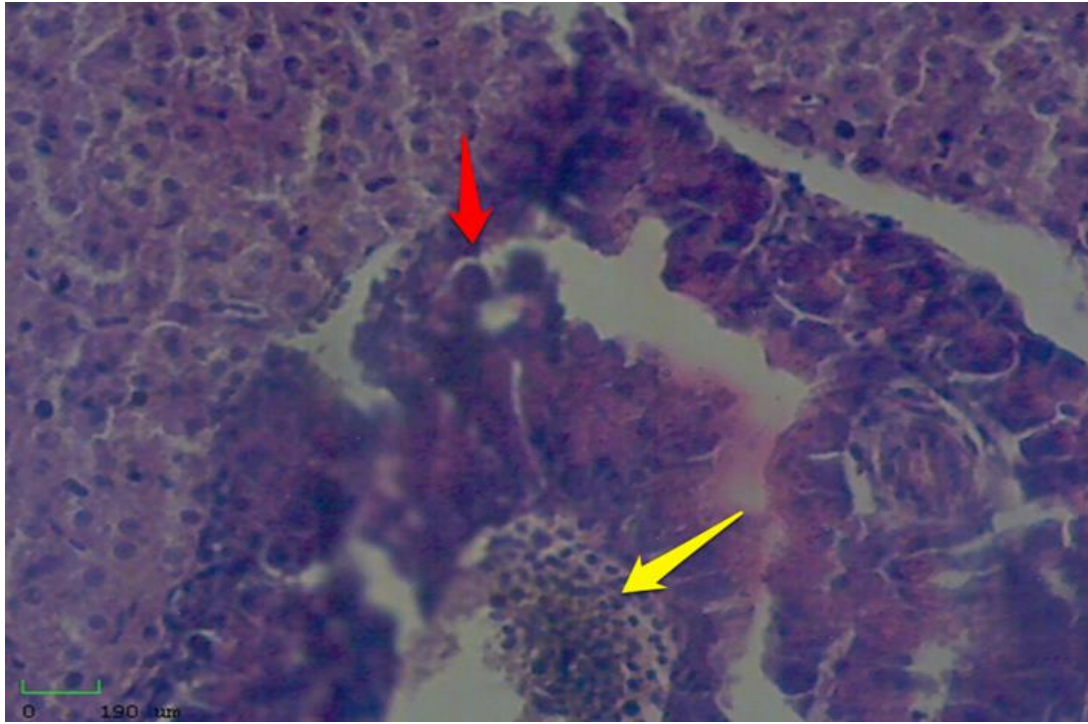


Plate (4): Infected spleen with *P. aeruginosa* of chitosan group. Note leucocytosis (yellow arrow) and accumulation of inflammatory cells around blood vessel (red arrow) (H & E, 400x).

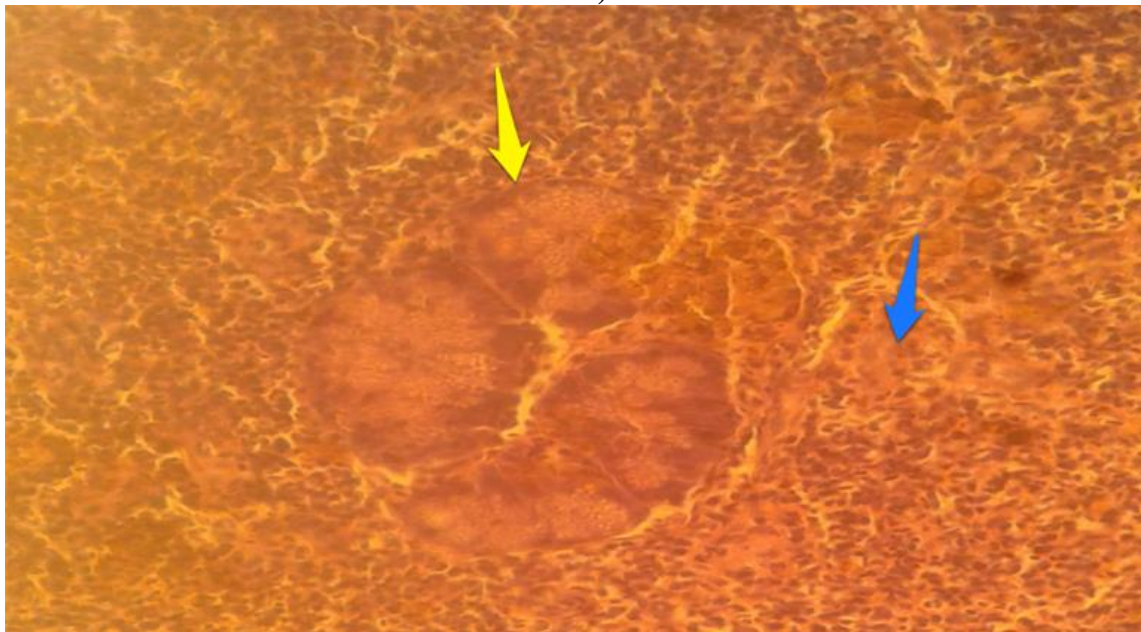


Plate (5): Infected spleen of chitosan group. Note accumulation of macrophages and degeneration (blue arrow) and presence of focus from phagocytic macrophages (yellow arrow). (H & E, 400x).

macrophages (yellow arrow), and presence of fibrin.

Histological effect of dietary ciprofloxacin on liver and spleen challenged with *P. aeruginosa*

Plate (6) displayed infected liver with *P. aeruginosa* of antibiotic group (0.02%) after 90 days. Narrowing of the sinusoid (black arrow) due to swelling of hepatocytes with infiltration with inflammatory cells (green arrow) and hyperplasia in the bile duct (yellow arrow) were noticed, while plate (7) exhibited abnormal accumulation of lymphatic follicles (yellow arrow). Plate (8) displayed infected liver with *P. aeruginosa* of

antibiotic group (0.02%) post infection (14th days after infection. Swelling of hepatocytes (red arrow), necrosis (yellow arrow) and distribution of inflammation cells (black arrow) were noticed. Plate (9) revealed infected spleen with *P. aeruginosa* of antibiotic group. Thickness at the wall capsule (blue arrow) and presence of homogeneous pinkish matter around arteriole in the red pulp (red arrow) with lymphocytosis in the white pulp (yellow arrow) were noticed. Plate (10) showed infected liver with *P. aeruginosa* of positive control group. Severe degeneration (blue arrow), especially around hepatic vein with congestion (yellow arrow) and fibrosis in the hepatic tissue (black arrow) were noticed.

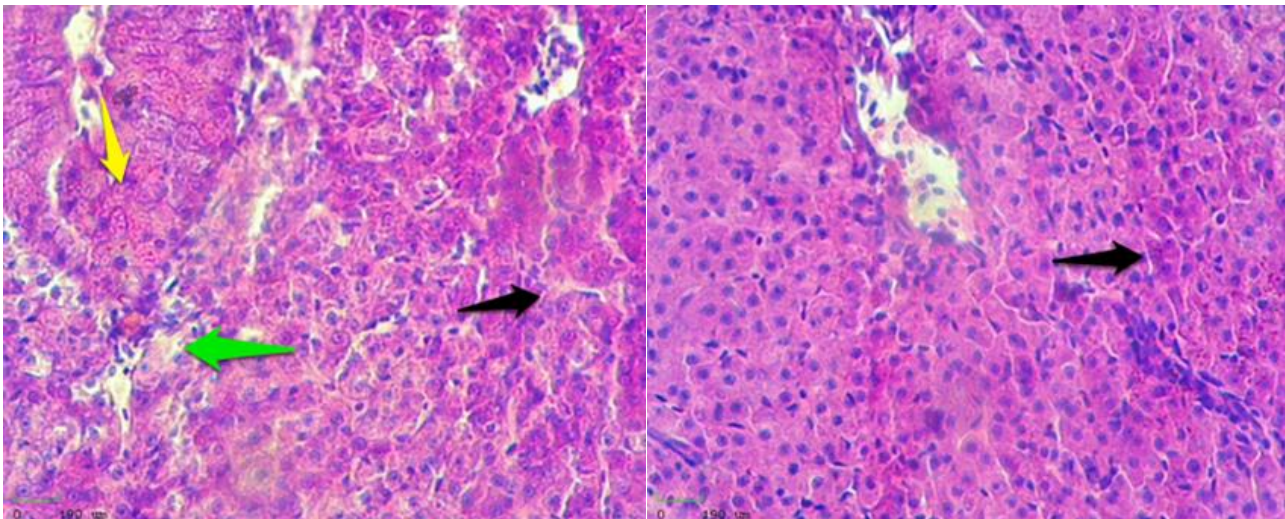


Plate (6): Infected liver with *P. aeruginosa* of antibiotic group (0.02%) after 90th days. Note narrowing of the sinusoid (black arrow) due to swelling of hepatocytes with infiltration with inflammatory cells (green arrow) and hyperplasia in the bile duct (yellow arrow). (H & E, 400x).

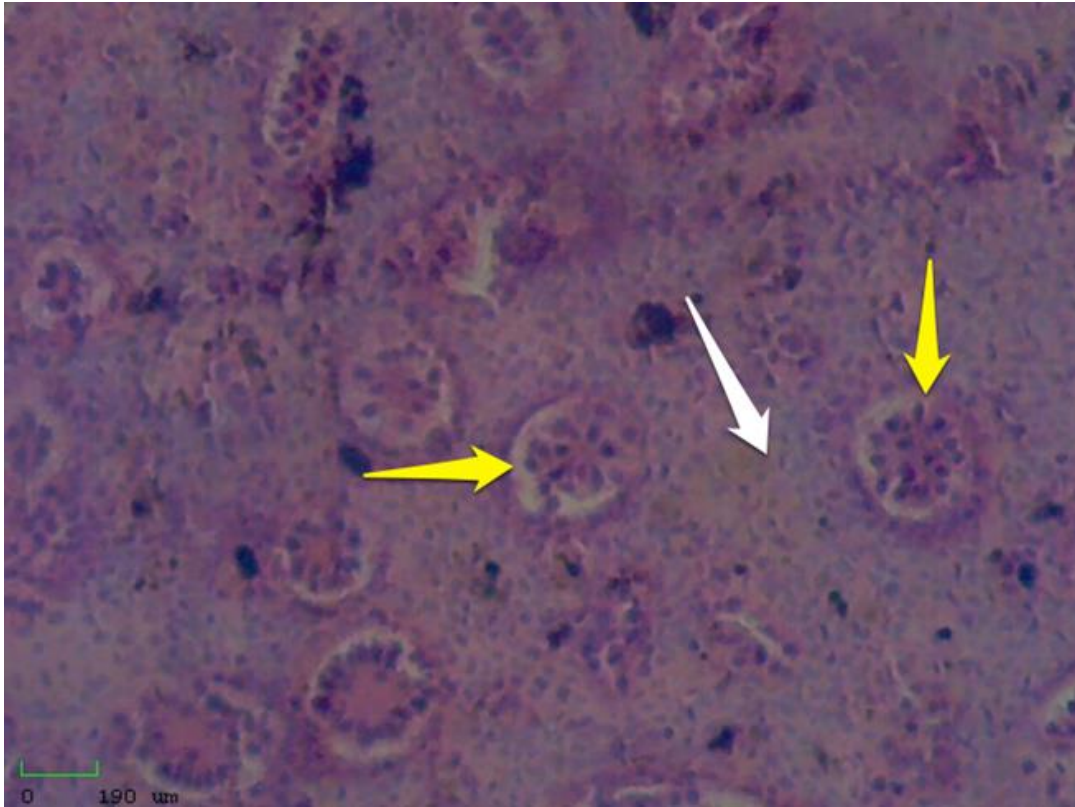


Plate (7): Infected spleen with *P. aeruginosa* of antibiotic group at 90th days. Note abnormal accumulation of lymphatic follicles (yellow arrow) and hyperplasia (white arrow). (H & E, 400x).

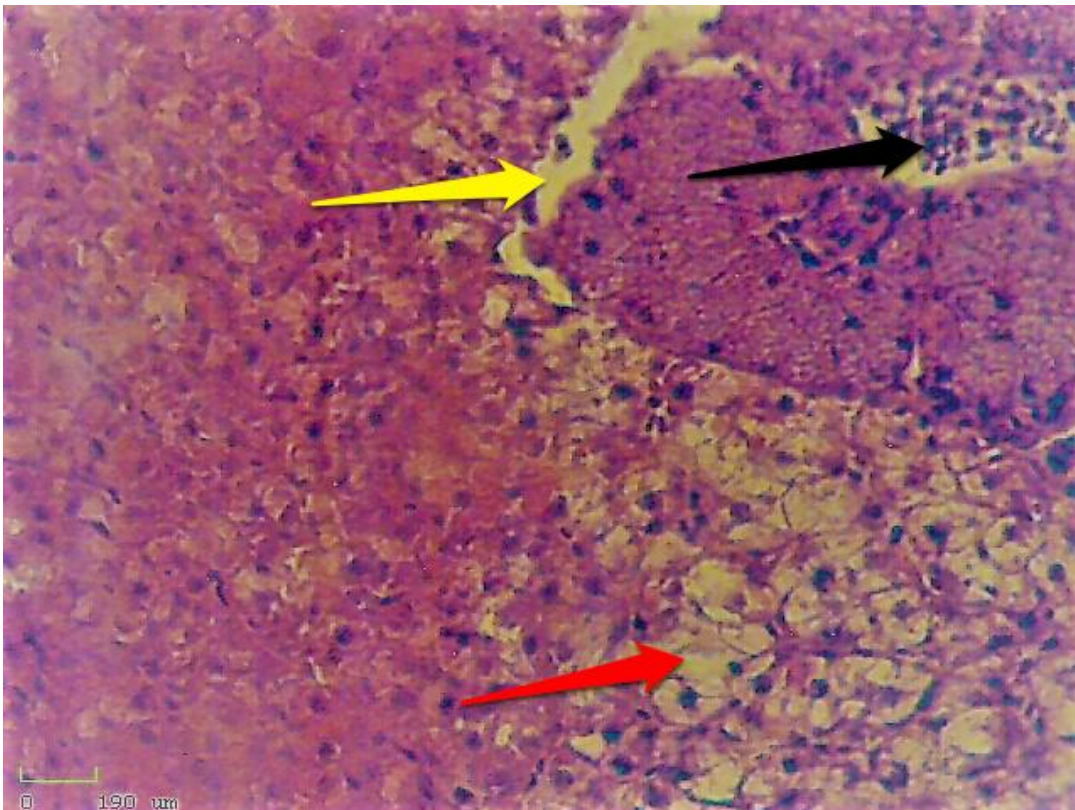


Plate (8): Infected liver with *P. aeruginosa* of antibiotic group (0.02%) post infection (14th days after infection). Note swelling of hepatocytes (red arrow), necrosis (yellow arrow) and distribution of inflammation cells (black arrow). (400x). (H & E, 400x).

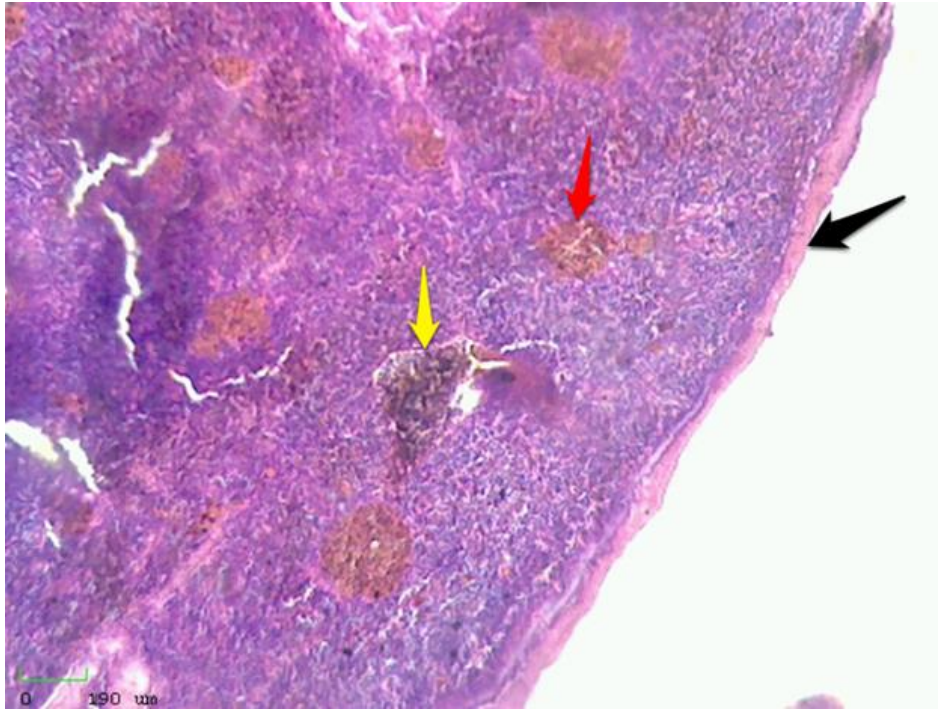


Plate (9): Infected spleen with *P. aeruginosa* of antibiotic group post infection. Note thickness at the wall capsule (blue arrow) and presence of homogeneous pinkish matter around arteriole in the red pulp (red? arrow) with lymphocytosis in the white pulp. (H & E, 400x).

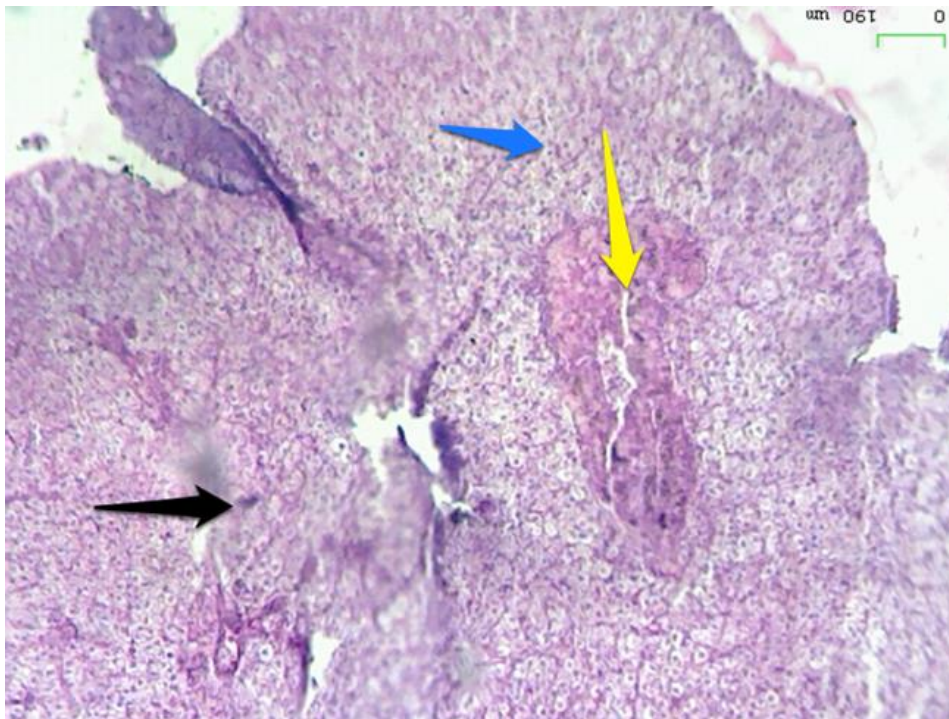


Plate (10): Infected liver with *P. aeruginosa* of positive control group. Note the severe degeneration (blue arrow), especially around hepatic vein with congestion (yellow arrow) and fibrosis in the hepatic tissue (black arrow). (H & E, 400x).

Discussion

Percentage of fish mortality

It is clear from the results of fig. (1) that the groups of dietary chitosan and combined chitosan (dietary + external) achieved the lowest percentage of mortality, whereas antibiotic group came in third. However, approximately half of the perished fishes in the experiment belonged to the control group (43.61%). These positive results reinforce the fact that chitosan is affective as an antibacterial agent and as a protective agent for diseases by its effect on non-specific defence mechanisms (Kamali Najafabad *et al.*, 2016), intestine morphology, intestine microbiota and disease resistance (Chen *et al.*, 2014), thus led contribution to increase survivability of farmed fishes.

Histological effect of dietary chitosan on liver and spleen challenged with *P. aeruginosa*

Some pathological signs were appeared in the tissues among different groups. Vacuolation was happened due to death of the cells and degeneration of hepatocytes that led to abnormal appearance. These changes caused formation of space and vacuoles in the liver tissue (Huizinga *et al.*, 1979). The reason of occurring these pathological changes is due to high intensity of bacteria which directed to destruction of hepatocytes and obstruction of metabolism in the liver. Furthermore, swelling of hepatic tissues means expansion of their volume and hence causing blocking and narrowing of sinusoids caused by *P. aeruginosa*. This type of bacteria has the ability to escape from fish defence immunity and hence the acute inflammation cannot be overcome by fish defence (Pier & Ramphal, 2005). It is known that *P. aeruginosa* causes a high pathological changes in humans or in

animals. The histopathological changes in the current study are similar to those of Magdy *et al.* (2014) on African catfish *Clarias gariepinus*. The noted necrosis in the liver means that the cells were injured and failure of the blood to supply (cell death) owing to the biological interaction between the invasive bacteria and immunological defence of the host, so called "antibody and antigen reaction" (Huizinga *et al.*, 1979).

The spleen suffered from the so evident haemorrhage and distribution of lymphoid follicle of white pulp. The reason may be due to increasing of defence cells in the tissue which indicates that immune-stimulation was taken in chitosan group after 90 days of the experiment. This comes in agreement with the role of chitosan as immune stimulation in many fish species (Meshkini *et al.*, 2012). Mori *et al.* (2005) explained that chitosan activates macrophages by forming large amount of complex histological compounds (class I and class II) and multi cellular receptors assist in prolonging cell life. Moreover, the chitosan increases dilation of blood vessels "Neovascularization". Alishahi *et al.* (2014) indicated that supplementation of food with 0.5 and 1% chitosan induced enhancement of some immune parameters and resistance against *Aeromonas hydrophila* infection in *C. carpio*.

Histopathological changes in spleen after challenge with *P. aeruginosa*

After challenging the fishes of chitosan group by *P. aeruginosa*, and with beginning of appearance of the pathogenic symptoms on the surface of fishes, the external 2% chitosan solution was used to conform combined chitosan group (dietary chitosan + external chitosan). The histological changes in the spleen were represented with macrophage aggregation and degeneration. These changes

are considered as an immune response to the body resulting from entrance of pathogens into host body, In other hand, the fishes with dietary chitosan during 90 days gave enough immunity to resist the disease agent, which gave the fishes to use the defence mechanisms against the pathogens such as the appearance of the focus from phagocytic macrophages and being leukocytosis. The present results confirm the result of Mustafa *et al.* (2014) when they found that the chitosan increased the immunity of fishes and resist the fishes against the disease agents. Some studies exhibited that plant extracts could be successful substitution instead of antibiotics so they are friendly to environment and they have no side effect on fish health (Meshkini *et al.*, 2012; Iheanacho *et al.*, 2017).

Histological effect of dietary Ciprofloxacin (CYPRO) on liver and spleen challenged with *P. aeruginosa*

Histological section of fish's liver of dietary antibiotic group showed narrowing sinusoid due to swelling of hepatocytes and infiltration of inflammation cells and hyperplasia. Similar results were found by Magdy *et al.* (2014) when the liver exerted degeneration changes in the shape of cytoplasm and the correlation and intensification of the nucleus, signs of shrinking liver cells with increased sinusoidal blood spaces and hepatic blood vessels associated with enlargement of the wall of blood vessels due to bacterial infection (*Pseudomonas* spp.). This mean of the antibiotics used in the current study failed to stimulate the immunity and resistance toward the disease. Antibiotics supposed to make fish resistance to the disease even greater. This confirms with Yanong (2003), when he demonstrated that antibiotics themselves do not heal the fish but only control the growth of bacteria, and most of the antibiotics are

resistant to bacteria that are positive for Gram stain, in contrast to the vast majority of Gram-negative bacteria that cause diseases in fishes. So, the antibiotics used in the experiment did not give immunological and therapeutic effectiveness and it is not recommended for use in dipping bath therapeutics (Manage, 2018).

When dietary antibiotic of infected fishes were treated, it became clear that there was a thickening at the wall capsule of spleen with connective tissue. This means that the antibiotics did not play role in the treatment because the bacteria used in this study, and most bacterial species, are Gram- negative which are resistant to antibiotics and can be transmitted directly and cause infection in humans (Liyanage & Manage, 2015), through direct contact with water or aquatic organisms via drinking water or circulation and consumption of aquaculture products (Tamura *et al.*, 1992). Yanong (2003) proved that antibiotics do not cure the fishes and control only the bacterial growth in large fishes that have immune system enough to eliminate. Also, he found the presence of a homogeneous pink material around the arteriole in the red pulp, in addition to cell proliferation. The lymphatic pulp in white pulp can be attributed to high immunity.

Conclusions

Several histological changes in the liver and spleen of fishes treated with chitosan and antibiotics, which were experimentally infected with *P. aeruginosa* in both two periods, showed the presence of resistance against the disease as evidence of a decrease mortality ratio for both groups in comparison with the positive control. Another advantage is that the histopathological changes in the liver and spleen of chitosan revealed less

pathogenesis compared with that in antibiotic sample.

Acknowledgements

The authors appreciated to thank staff of Department of Fisheries and Marine Resources, College of Agriculture, University of Basrah. Sincere thanks are due to Dr. Majid M. Taher, Aquaculture Unit for providing the space to do the research, Prof Zainab W. Khudhaer, Department of Pathology and Poultry Diseases, College of Veterinary Medicine, University of Basrah for her advice in diagnosis of the pathological changes, Dr. Saher S. Gorge, Department of Food Science, College of Agriculture, University of Basrah for her assistance in the bacteriological analysis, Prof. Dr. Sabah M. Al-Shatty, Department of Food Science, College of Agriculture, University of Basrah for confirming the identification of the bacteria.

Conflict of interest: The authors declare that they have no conflict of interest.

Ethical approval: all applicable national and international guidelines for the care and use of animals were followed.

References

- Alishahi, M.; Esmaili Rad, A.; Zarei, M. & Ghorbanpour, M. (2014). Effect of dietary chitosan on immune response and disease resistance in *Cyprinus carpio*. Iran. J. Vet. Med., 8(2):125-133.
- Amrevuawho, M.A.; Akinyemi, A.A.; Ezeri, O.G.N.; Bankole, O.M. & Takeet, O.V. (2014). Pathological study of *Clarias gariepinus* Burchell, 1822) sub-adult artificially infected with *Pseudomonas aeruginosa*. Braz. J. Aquat. Sci. Technol. 18(2): 65-70.
- Austin, B. & Austin, D.A. (2007). Bacterial fish pathogens; disease of farmed and wild fish, 6th ed. Springer Publ., London: 319pp.
- Chen, Y.; Zhu, X.; Yang, Y.; Han, D.; Jin, J. & Xie, S. (2014). Effect of dietary chitosan on growth performance, haematology, immune response, intestine morphology, intestine microbiota and disease resistance in gibel carp (*Carassius auratus gibelio*). Aquac. Nutr., 20(5): 532-546.
- Clatworthy, A.E.; Lee, J.S.; Leibman, M.; Kostun, Z.; Davidson, A.J. & Hung, D.T. (2009). *Pseudomonas aeruginosa* infection of zebrafish involves both host and pathogen determinants. Infect. Immun., 77: 1293-1303.
- Flores-Miranda, B.M.; Espinosa-Plascencia, A.; Gómez-Jiménez, S.; López-Zavala, A.A.; González-Carrillo, H.H. & Bermúdez-Almada, M.D.C. (2012). Accumulation and elimination of enrofloxacin and ciprofloxacin in tissues of shrimp *Litopenaeus vannamei* under laboratory and farm conditions. Int. Scholarly Res. Netw. (ISRN) Pharm., 2012, Article ID 374212, 7pp. doi:10.5402/2012/374212.
- Garvey, J.S.; Cremer, N.E. & Sussdorf, D.H. (1977). Methods in Immunology. 3rd ed. W.A. Benjamin, Inc. Massachusetts: 545pp.
- Harikrishnan, R.; Kim, J.-S.; Balasundaram, C. & Heo, M.S. (2012). Dietary supplementation with chitin and chitosan on haematology and innate immune response in *Epinephelus bruneus* against *Philasterides dicentrarchi*. Exp. Parasitol., 131: 116-124.
- Harley, J. & Prescott, L. (2002). Bacterial Morphology and Staining. Laboratory

- Exercises in Microbiology. 5th ed., McGraw-Hill, New York: 320pp.
- Huizinga, H.W.; Esch, G.W. & Hazen, T.C. (1979). Histopathology of red-sore disease (*Aeromonas hydrophila*) in naturally and experimentally infected largemouth bass *Micropterus salmoides* (Lacepede). J. Fish Dis., 2(4): 263-277.
- Humason, G.L. (1972). Animal Tissue Techniques 3rd ed., W. H. Freeman, San Francisco: 641pp.
- Iheanacho, S.C.; Ogunji, J.O.; Ogueji, E. O.; Nwuba, L.A.; Nnatuanya, I.O.; Ochang, S. N.; Mbah, C.E.; Usman, I. & Haruna, M. (2017). Comparative assessment of ampicillin antibiotic and ginger (*Zingiber officinale*) effects on growth, haematology and biochemical enzymes of *Clarias gariepinus* Juvenile. J. Pharmacog. Phytochem., 6(3): 761-767.
- Kamali Najafabad, M.; Imanpoor, M.R.; Taghizadeh, V. & Alishahi, A. (2016). Effect of dietary chitosan on growth performance, hematological parameters, intestinal histology and stress resistance of Caspian kutum (*Rutilus frisii kutum* Kamenskii, 1901) fingerlings. Fish Physiol. Biochem., 42(4): 1063-1071. doi: 10.1007/s10695-016-0197-3.
- Koh, C.B.; Romano, N.; Zahrah, A.S. & Ng, W.K. (2016). Effects of a dietary organic acids blend and oxytetracycline on the growth, nutrient utilization and total cultivable gut microbiota of the red hybrid tilapia, *Oreochromis* sp., and resistance to *Streptococcus agalactiae*. Aquac. Res., 47(2): 357-369.
- Lin, S.; Mao, S.; Guan, Y.; Luo, L.; Luo, L. & Pan, Y. (2012). Effects of dietary chitosan oligosaccharides and *Bacillus coagulans* on the growth, innate immunity and resistance of koi (*Cyprinus carpio koi*). Aquaculture, 342: 36-41.
- Liyanage, G. & Manage, P. (2015). Presence of tetracycline and oxytetracycline resistant bacteria and resistant genes in effluent water of Zoological Garden, Sri Lanka. In Proc. 11th Int. Acad. Conf. Dev. Sci. Technol. (IACDST-2015): 11-14.
- Magdy, I.; El-Hady, M.; Ahmed, H.; Elmeadawy, S. & Kenwy, A. (2014). A contribution on *Pseudomonas aeruginosa* infection in African catfish (*Clarias gariepinus*). Res. J. Phar. Biol. Chem. Sci., 5(5): 575-588.
- Maqsood, S.; Singh, P.; Samoon, M.H. & Balange, A.K. (2002). Effect of dietary chitosan on non-specific immune response and growth of *Cyprinus carpio* challenged with *Aeromonas hydrophila*. Int. Aquat. Res., 2: 77-85.
- Manage, P.M. (2018). Heavy use of antibiotics in aquaculture, emerging human and animal health problems: A review. Sri Lanka J. Aquat. Sci., 23(1): 13-27.
- Meshkini, S., Tafy, A.A., Tukmechi, A. & Farhang-Pajuh, F. (2012). Effects of chitosan on hematological parameters and stress resistance in rainbow trout (*Oncorhynchus mykiss*). Vet. Res. Forum, 3(1): 49-54.
- Mori, T.; Murakami, M.; Okumura, M.; Kadosawa, T.; Uede, T. & Fujinaga, T. (2005). Mechanism of macrophage activation by chitin derivatives. J. Vet. Med. Sci., 67(1): 51-56.
- Mustafa, S.A.; Alfaragi, J.K. & Aref, Z. (2014). The influence of chitosan on immune status and survival rate of *Cyprinus carpio* L. Kufa J. Vet. Med. Sci., 5(2): 93-104.

- Pham, D.K.; Chu, J.; Do, N.T.; Brose, F.; Degand, G.; Delahaut, P.; De Pauw, E.; Douny, C.; Nguyen, K.V.; Vu, T.D.; Scippo, M.L. & Wertheim, H.F. (2015). Monitoring antibiotic use and residue in freshwater aquaculture for domestic use in Vietnam. *Ecohealth*, 12(3): 480-489. doi: 10.1007/s10393-014-1006-z.
- Phennicie, R.T.; Sullivan, M.J.; Singer, J.T.; Yoder, J.A. & Kim, C.H. (2010). Specific resistance to *Pseudomonas aeruginosa* infection in zebrafish is mediated by the cystic fibrosis transmembrane conductance regulator. *Infect. Immun.*, 78(11): 4542-4550. doi: 10.1128/IAI.00302-10.
- Pier, G. & Ramphal, R. (2005). *Pseudomonas aeruginosa*. *Principles Pract. Infect. Dis.*, 6(2): 2587-2615.
- Rocchetta, H.L.; Burrows, L.L. & Lam, J.S. (1999). Genetics of O-antigen biosynthesis in *Pseudomonas aeruginosa*. *Microbiol. Mol. Biol. Rev.*, 63: 523-553.
- Tamura, Y.; Suzuki, S. & Sawada, T. (1992). Role of elastase as a virulence factor in experimental *Pseudomonas aeruginosa* infection in mice. *Microbial Pathogenesis*, 12(3): 237-244.
- Watts, J.E.M.; Schreier, H.J.; Lanska, L. & Hale, M.S. (2017). The rising tide of antimicrobial resistance in aquaculture: Sources, sinks and solutions. *Mar. Drugs*, 15(6): E158. doi: 10.3390/md15060158.
- Yanong, R.P. (2003). Use of antibiotics in ornamental fish aquaculture. *Univ. Fla. Coop. Ext. Serv., IFAS Ext.*: 7pp.